

A new technique for repeated biopsies of the mammary gland in dairy cows allotted to Latin-square design studies

Luciano S. de Lima, Eric Martineau, Francilaine E. De Marchi, Marie-France Palin, Geraldo T. dos Santos, H el ene V. Petit

Abstract

The objective of this study was to develop a technique for carrying out repeated biopsies of the mammary gland of lactating dairy cows that provides enough material to monitor enzyme activities and gene expression in mammary secretory tissue. A total of 16 Holstein cows were subjected to 4 mammary biopsies each at 3-week intervals for a total of 64 biopsies. A 0.75-cm incision was made through the skin and subcutaneous tissue of the mammary gland and a trocar and cannula were inserted using a circular motion. The trocar was withdrawn and a syringe was plugged into the base of the cannula to create a vacuum for sampling mammary tissue. To reduce bleeding, hand pressure was put on the surgery site after biopsy and skin closure and ice was applied for at least 2 h after the biopsy using a cow bra. The entire procedure took an average of 25 min. Two attempts were usually enough to obtain 800 mg of tissue. Visual examination of milk samples 10 d after the biopsy indicated no trace of blood, except in samples from 2 cows. All wounds healed without infection and subcutaneous hematomas resorbed within 7 d. There was no incidence of mastitis throughout the lactation. This technique provides a new tool for biopsy of the mammary gland repeated at short intervals with the main effect being a decrease in milk production. Although secondary complications leading to illness or death are always a risk with any procedure, this biopsy technique was carried out without complications to the health of animals and with no incidence of mastitis during the lactation.

R esum e

Cette  tude a  t e conduite avec l'objectif de d ecrire une technique pour laquelle les biopsies de la glande mammaire des vaches laiti eres en lactation sont r ep et ees. Un total de 16 vaches Holstein ont  t e soumises chacune   4 biopsies de la glande mammaire   un intervalle de 3 semaines pour un total de 64 biopsies. Une incision de 0,75 cm a  t e faite   travers la peau et le tissu sous-cutan e de la glande mammaire, et un trocart et une canule ont  t e ins er es en utilisant un mouvement circulaire. Le trocart a  t e retir e et une seringue a  t e attach ee   la base de la canule pour cr eer un vacuum afin d' chantillonner le tissu mammaire. Afin de r eduire le saignement, une pression manuelle a  t e appliqu ee sur le site de la chirurgie apr es la biopsie et la suture de l'incision de la peau, et de la glace a  t e appliqu ee pour au moins 2 h apr es la biopsie en utilisant une brassi ere pour vache. La proc edure enti ere a exig e une moyenne de 25 min et deux essais ont habituellement  t e suffisants pour obtenir 800 mg de tissu. Un examen visuel des  chantillons de lait n'ont indiqu e aucune pr esence de sang 10 jours apr es la biopsie sauf pour deux vaches. Les plaies ont toutes gu eries sans infection, et les h ematomes sous-cutan es se sont r esorb es   l'int erieur d'une p eriode de 7 jours. Il n'y a eu aucune incidence de mammite durant la lactation. Cette technique d ecrit un nouvel outil de biopsie de la glande mammaire r ep et e   de courts intervalles o  l'effet principal a  t e une baisse de la production laiti ere. Bien que les complications secondaires entrainant la maladie ou la mort soient toujours un risque avec toute proc edure, cette technique de biopsie a  t e faite sans complications pour la sant e des animaux et il n'y a eu aucune incidence de mammite durant la lactation.

(Traduit par les auteurs)

Introduction

Sampling of mammary tissue in dairy cows through biopsy has long been considered a difficult and even an uncertain task due to its effects on milk production and mammary health (1). In studies with dairy cows, Latin-square designs are widely used mainly because they provide a rapid and powerful response to treatments (2). When biopsies of the mammary gland are taken repeatedly in studies such as Latin-square experiments, however, bleeding and mastitis may

occur that will adversely affect milk production in subsequent periods of the experiment and alter the response to treatments. As the amount of tissue obtained from biopsies limits the number of laboratory analyses that can be done, a technique is needed that provides large-core samples and minimizes damage to the mammary gland. An adequate technique of biopsy may reduce variation in results and secondary complications to animals.

Over the years, a number of methods of mammary gland biopsy have been used in dairy cows (1,3,4). One of the most popular

Departamento de Zootecnia, Universidade Estadual de Maring a, Maring a, PR 87020-900, Brazil (Lima, Marchi, Santos); Clinique V et erinaire de Coaticook, Coaticook, Qu ebec J1A 1P9 (Martineau); Dairy and Swine Research and Development Centre, Agriculture and Agri-Food Canada, 2000 College Street, Sherbrooke, Qu ebec J1M 0C8 (Palin, Petit).

Address all correspondence to Dr. H el ene V. Petit; telephone: 819-780-7210; fax: 819-564-5507; e-mail: helene.petit@agr.gc.ca

Received October 6, 2015. Accepted February 22, 2016.

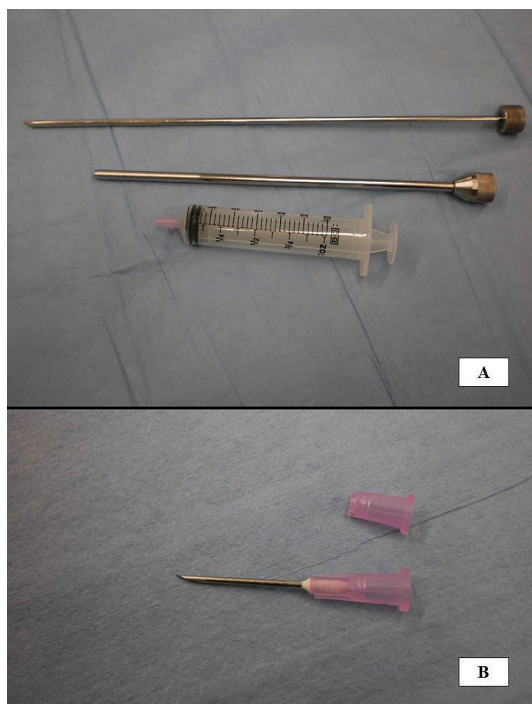


Figure 1. A — The 3 pieces of the biopsy instrument; and B — The base of the 3.8-cm needle used to plug the syringe into the base of the cannula. The needle itself was removed and only the base was used to connect to the 30-mL syringe with slip tip.

techniques is that developed by Farr et al (1), in which a core of mammary secretory tissue is extracted using a stainless steel cannula with a retractable blade at the cutting edge and a slow-speed electric motor to rotate the biopsy instrument. Our team has previously used this procedure in a few Latin-square experiments and has noticed trauma to the mammary gland and excessive bleeding. Indeed, VanKlompberg et al (3) have reported that the drill-operated instrument proposed in this earlier study (1) may lead to excessive blood loss. As this may cause discomfort and health problems for cows subjected to repeated sampling of the mammary gland, such as those carried out in Latin-square experiments, the objective of this study was to develop a biopsy technique that can be used frequently on lactating dairy cows and that provides enough material to monitor enzyme activities and gene expression in mammary secretory tissue.

Materials and methods

Animals

All animals were cared for in accordance with the guidelines of the Canadian Council on Animal Care (5) and all biopsy procedures were approved by the local Animal Care Committee. Individual observations of 16 Holstein cows from 2 separate lactating cow-feeding trials carried out as replicated 4×4 Latin-square design were used. The trials were conducted in the same year with different treatment diets and using different cows. Details on dietary treatments and experimental procedures of experiments 1 and 2 have been published previously (6,7, respectively).



Figure 2. Ice applied to the biopsy site using a cow bra.

Briefly, the experimental diets were based on corn silage and grass silage. In experiment 1, the effects of dietary flax meal and abomasal infusion of flax oil were evaluated, while in experiment 2, the effects of dietary flax meal and abomasal infusion of sunflower oil were assessed. Cows ranged from 35 to 105 d in lactation and 2 to 4 d in parity. They were housed in individual stalls with free access to water and were fed twice a day for *ad libitum* intake [100 g/kg body weight (BW) of refusals as fed]. Cows were milked twice daily and milk production was recorded at every milking.

Preparation, sedation, and pain management

All cows were submitted to the California Mastitis Test (Dairy Research Products, Ancaster, Ontario) before each biopsy to estimate somatic cell counts and to detect the presence of mastitis. On the day before the biopsy, udders were clipped to facilitate cleaning and aseptic procedures. On the day of the biopsy, cows were placed in a restraining cage and mildly sedated with an injection of 10 mg of xylazine (Zoetis Canada, Kirkland, Quebec) in the coccygeal vein. A 10-cm² piece of skin on the upper portion of the udder hindquarter was washed and aseptically prepared 3 times with 70% alcohol and 2% chlorhexidine acetate solution (Hibitane; Wyeth Animal Health, Guelph, Ontario). Before the last washing with alcohol and Hibitane, the biopsy site was anesthetized by injecting 3 mL (1 mL intradermal and 2 mL subcutaneous) of lidocaine hydrochloride (HCL) 2% (Bimeda-MTC Animal Health, Cambridge, Ontario).

Design of biopsy instrument

The biopsy instrument consisted of 3 main pieces: a trocar, a cannula, and a 30-mL syringe used to create a vacuum (Figure 1A). The trocar was made according to the design of Hughes (8), which was originally intended for liver biopsy in cattle. Both trocar and cannula were made of stainless steel. The cannula was 31 cm long, with an outer diameter of 9.5 mm and an inner diameter of 8 mm. The trocar was 34 cm long with a diameter that fit snugly into the cannula. The base of the trocar had a knurled end to allow a better grip with the fingers while carrying out the procedure. It is worth noting that the biopsy instrument described in the present experiment is not the

standard one used to obtain a percutaneous liver specimen in clinical cases where a Tru-Cut biopsy needle is commonly used.

Biopsy of mammary tissue

All biopsy instruments were autoclaved before use. Biopsies were carried out 6 h after the morning milking as previously described (1). Mammary secretory tissue was obtained from the junction of the upper and middle third of the hindquarters. The left and right hindquarters of the udder were alternated from one experimental period to another and biopsies were taken at least 10 cm away from the first site when a quarter was used for a second time. The mammary gland of cows was examined by ultrasonography using a Concept/MCV Veterinary Ultrasound Scanner equipped with a linear array 5 MHz probe (Tokyo Keiki, Tokyo, Japan) before skin incision to avoid any large subcutaneous blood vessels.

A 0.75-cm incision was then made through the skin and subcutaneous tissue with a scalpel. The trocar and cannula were inserted through the gland capsule using a circular motion. The tip of the cannula was beveled inward to form a sharp cutting edge and to allow easy penetration of the mammary gland. The trocar was then withdrawn and the cannula was driven deep enough to reach into the mammary parenchyma, while applying a circular motion with the hands to properly cut a core of mammary tissue and fill up the cannula. A 30-mL slip-tip syringe (Becton Dickinson, Rutherford, New Jersey, USA) was then plugged into the base of the cannula using a 3.8-cm needle (Figure 1B). The needle itself was removed in order to use only the base to connect to the 30-mL slip-tip syringe. Mammary secretory tissue samples were drawn into the cannula by way of a vacuum created by the syringe by rotating the cannula in a circular motion. In order to detach the distal part of the biopsy and leave it free, the cannula was then removed from the mammary gland, again using a circular motion.

Cores of 800 mg (wet weight of mammary tissue) were required in order to conduct enzyme activities and gene expression analyses. If not enough mammary tissue was obtained in the first attempt, another core was obtained immediately after, using the same 0.75-cm incision. It was always attempted to avoid reaching the abdomen and to cut at different angles, with the first cut at a lower angle than the second one. Hand pressure was applied to the surgery site between attempts, after biopsy, and after skin closure to control bleeding. The skin incision was closed with a cruciate polydioxanone monofilament synthetic absorbable suture (PDS II 2-0 CP-1; Ethicon, Cornelia, Georgia, USA).

Postoperative care

A chemical bandage (Aluspray; Neogen, Lexington, Kentucky, USA) was applied to the skin of the mammary gland to protect the incision from infections. To reduce bleeding, ice was applied to the incision site for at least 2 h after the biopsy using a cow bra (Figure 2). An intramuscular dose (30 mL) of penicillin (Pen-aqueous; Agripharm Products, Westlake, Texas, USA) was given immediately after the biopsy and twice a day for the next 4 d to prevent wound infection, following the procedure used for large animals at the Faculté de Médecine Vétérinaire in St-Hyacinthe, Quebec. Within 2 h of the biopsy, cows were hand-milked to remove intramammary blood clots. Cows were hand-stripped as required at each milking

over the next 4 to 7 d until all blood clots were removed. Body temperature was monitored once daily for 8 d after the biopsy. The skin sutures were removed 7 to 10 d after the biopsy.

Statistical analysis

Data on milk production, i.e., before and after biopsy and decrease in milk production after biopsy, were analyzed as repeated measurements using the MIXED procedure of SAS (SAS 2000; SAS Institute, Cary, North Carolina, USA) and covariance structures were modeled separately for each variable. Main sources of variation were square, period, and biopsy considered as fixed effects and cow within square as a random effect. When the 2 experiments were analyzed together, the experiment was considered as a fixed effect. Results were reported as least squares means with standard error of the mean (SEM). Significant differences were set at $P \leq 0.05$.

Results

Ultrasonography of the mammary gland was carried out in the biopsies of the first 8 cows and revealed that, despite the presence of large vessels, there was little damage from the present biopsy technique. It was therefore decided to discontinue the practice for the rest of the biopsies. Each of the 16 cows was subjected to 4 biopsies every 3 wk for a total of 64 mammary biopsies. Because the cows were mildly sedated, they were calm and easy to handle throughout the procedure, which saved time between biopsies carried out on different animals on the same day. The entire procedure took an average of 25 min from sedation to skin closure.

After the biopsies, no cows had to be removed from the experiments due to complications and none experienced fever as determined by daily monitoring of body temperature. Although there was no control group without a biopsy to compare the effects of the surgical procedure on health status and feed intake, cows were healthy and dry matter intake was slightly reduced from 30.5 to 28.3 kg/d (average of the 4 d before and after the biopsy, respectively).

Using the biopsy instrument, cores of 800 mg (wet weight of mammary secretory tissue) could be obtained from 1 biopsy, although most samples ranged from 200 to 700 mg. As many as 5 attempts were made during a given session to obtain an adequate amount of sample, although an average of 2.43 ± 0.84 attempts were enough to obtain the 800 mg required.

Most cows had some bleeding within 24 h of the biopsy. Although no blood loss counts were done and the precise amount of blood lost could therefore not be determined, most cows lost only a few milliliters of blood. Careful hand-stripping was enough to remove clotted blood from the glands. Most glands were free of blood clots within the first 24 h of the biopsy and no anti-bleeding drugs were required. No difference in bleeding was observed between the first and following biopsies. Visual examination revealed the presence of blood in milk for most cows up to 6.11 ± 0.78 d after the biopsy. The same 2 cows showed some residual blood in milk by day 10 post-biopsy in all 4 experimental periods.

All biopsy wounds healed without infection and subcutaneous hematomas resorbed within 7 d. Although no clinical mastitis was observed for any of the biopsied cows throughout the remainder of lactation, the biopsy procedure decreased ($P < 0.0001$) milk

Table I. Descriptive data of milk production of Holstein cows subjected to 4 biopsies of the mammary gland at 21-day intervals

	Period 1 (First biopsy)	Period 2 (Second biopsy)	Period 3 (Third biopsy)	Period 4 (Fourth biopsy)
Experiment 1 (<i>n</i> = 8)				
Milk production (kg/d)				
Pre-biopsy (4-day average)	36.6	33.1	30.5	25.6
Post-biopsy (4-day average)	34.5	28.1	27.4	23.1
Decrease	-2.1	-5.0	-3.1	-2.5
Experiment 2 (<i>n</i> = 8)				
Milk production (kg/d)				
Pre-biopsy (4-day average)	47.4	41.8	41.5	38.9
Post-biopsy (4-day average)	40.8	37.8	35.0	30.1
Decrease	-6.5	-4.0	-6.5	-8.8
Experiments 1 and 2 (<i>n</i> = 16)				
Milk production (kg/d)				
Pre-biopsy (4-day average)	42.0	37.4	36.0	32.3
Post-biopsy (4-day average)	37.7	32.9	31.2	26.6
Decrease	-4.3	-4.5	-4.8	-5.7

Table II. Average milk production before and after biopsy of the mammary gland in Holstein cows

	4-day average (kg/d)		SEM	<i>P</i> -value
	Before biopsy	After biopsy		
Experiment				
1 and 2 (<i>n</i> = 64)	36.9	32.1	1.19	< 0.0001
1 (<i>n</i> = 32)	31.5	28.3	0.67	< 0.0001
2 (<i>n</i> = 32)	42.4	35.9	0.90	< 0.0001

SEM — Standard error of mean.

production for each of the 4 periods (Table I). The average milk production decreased for 4 d after the biopsy compared to the 4 d before the biopsy ($P < 0.0001$) (Table II). This decrease in milk production after the biopsy averaged 2.8 kg/d in experiment 1 and this average decrease was greater ($P < 0.001$) in experiment 2 at 5.5 kg/d.

Discussion

This study developed a different technique than the one developed by Farr et al (1). In this last study, a core of secretory tissue was extracted using an electric-driven, rotating stainless steel cannula with a retractable blade at the cutting edge, which may lead to excessive bleeding (3). Conversely, in the present experiment, the trocar was inserted through the gland capsule with a gentle, manually driven circular motion and samples were withdrawn using the vacuum created by a syringe. The trocar used was originally intended for liver biopsy in cattle, although different from the standard instrument used to obtain percutaneous liver specimen in clinical cases where a tru-cut biopsy needle is commonly used.

Only 2 animals showed some residual blood in milk by day 10 post-biopsy, which suggests that these 2 cows had abnormal clot formation or coagulation time. There was no actual blood in the milk, however, and all cows had completely healed by the next biopsy 21 d later. Use of this biopsy instrument, applying pressure between and after biopsies, and putting ice on the incision site for at least 2 h after the biopsy likely helped to avoid excessive bleeding and accelerated healing of the mammary gland.

Samples of mammary secretory tissue obtained after 2 biopsies were usually considered large enough to carry out all tests required to determine enzyme activities and gene expression. Moreover, sampling once every 21 d allowed detection of statistical differences in enzyme activity and gene expression among cows subjected to various treatments assigned to Latin-square designs (6,7).

As already stated, milk production decreased after biopsies, with a greater decrease after the second experiment. Overall, milk production was higher in experiment 2 than in experiment 1 [45.5 compared to 32.6 kg/d, respectively (6,7)], which suggests that high-producing cows are more affected by biopsies. Nutrition projects were conducted in parallel using the same cows and it is worth noting that milk production was not affected by the dietary treatments in either experiment (6,7).

The decrease in average milk production after the biopsies is in agreement with the results of Farr et al (1) who reported lower milk production for 6.5 d after biopsy of the mammary gland when dairy cows were subjected to a procedure using an electric rotating cannula with a retractable blade at the cutting edge. Moreover, a similar decrease in milk production has been reported after 2 biopsies carried out 30 d apart by Oxender et al (4) who used scissors to carry out biopsies of the mammary gland in dairy cows. In general, these results suggest that lower milk production is normal immediately after a biopsy due to the trauma and stress of the procedure. The mammary gland has many blood vessels and blood supply is

extremely important for its function (9). Internal bleeding and clot formation could therefore impair blood supply to alveolar cells and obstruct milk ducts, thus lowering milk production.

Milk production decreased over time. Our results suggest that the trauma and stress of the repeated biopsies carried out over time likely contributed to lower milk production from the first to the fourth biopsy. Although the biopsy is clearly the most important factor that affected milk production in our experiment, it is well-known that several factors such as intake of dry matter and lactation stage also affect milk production. Indeed, the intake of dry matter decreased after each biopsy, which was likely due to the trauma and stress of the procedure. Nutritional studies were conducted at the same time as the present study and the use of non-steroidal anti-inflammatory drugs may have affected the response of measurements such as gene expression to feeding treatments. As a result, cows received only antibiotic treatment and no pain management. The decrease in intake of dry matter immediately after the biopsy could have contributed to decreased milk production as it is related to the amount of nutrients ingested by animals.

Lactation stage combined with other factors already discussed could also have influenced milk production. Indeed, there was a 63-day interval between the first and fourth biopsy and cows ranged from 35 to 105 d in milk, which meant that some cows were on the decreasing part of the lactation curve (10). It is well-established that apoptotic death of secretory cells in the mammary gland accounts for the decline in milk yield that follows peak production in dairy cows (11,12). Natural death of mammary secretory cells could therefore be at least partially responsible for the observed decline in total milk yield. This is supported by results reported by Capuco et al (13) who observed that milk yield declined by 23% from day 90 (peak of lactation) to day 240 of lactation, combined with a decline in epithelial mammary deoxyribonucleic acid (DNA) in multiparous Holstein cows milked twice a day. Similarly, Pollott (14) observed a decline of almost 11% in milk production of Holstein cows from peak of lactation (day 35) to day 90.

In conclusion, this biopsy technique successfully allows tissue sampling of the mammary gland to be repeated every 3 wk in lactating dairy cows allotted to Latin-square designs, with the aim of providing mammary secretory tissue samples large enough to monitor enzyme activity and gene expression. The procedure took an average of 25 min and ultrasonography was not required. Although secondary complications leading to illness or death are always a risk with any procedure, this biopsy technique was carried out without complications to the health of animals and there was no incidence of mastitis during the lactation.

Acknowledgments

This study was funded by Agriculture and Agri-Food Canada. The authors gratefully acknowledge the staff of the Dairy and Swine Research and Development Centre for their contribution to the present study. Special thanks to Danielle Beaudry for technical assistance.

Luciano S. de Lima and Francilaine E. De Marchi were recipients of a studentship and Geraldo T. dos Santos was the recipient of a fellowship from the Conselho Nacional de Desenvolvimento Científico e Tecnológico (CNPq-Brazil).

References

1. Farr VC, Stelwagen K, Cate LR, Molenaar AJ, McFadden TB, Davis SR. An improved method for the routine biopsy of bovine mammary tissue. *J Dairy Sci* 1996;79:543–549.
2. Robinson PH, Wiseman J, Udén P, Mateos G. Some experimental design and statistical criteria for analysis of studies in manuscripts submitted for consideration for publication. *Anim Feed Sci Technol* 2006;129:1–11.
3. VanKlombenberg MK, McMicking HF, Hovey RC. Technical note: A vacuum-assisted approach for biopsying the mammary glands of various species. *J Dairy Sci* 2012;95:243–246.
4. Oxender WD, Askew EW, Benson JD, Emery RS. Biopsy of liver, adipose tissue and mammary gland of lactating cows. *J Dairy Sci* 1971;54:286–288.
5. Canadian Council on Animal Care. *Guide to the Care and Use of Farm Animals in Research, Teaching and Testing*, Ottawa: CCAC, 2009.
6. Lima LS, Palin MF, Santos GT, Benchaar C, Petit HV. Effects of supplementation of flax meal and flax oil on mammary gene expression and activity of antioxidant enzymes in mammary tissue, plasma and erythrocytes of dairy cows. *Livest Sci* 2015;176:196–204.
7. De Marchi FE, Palin M-F, dos Santos GT, Lima LS, Benchaar C, Petit HV. Flax meal supplementation on the activity of antioxidant enzymes and the expression of oxidative stress- and lipogenic-related genes in dairy cows infused with sunflower oil in the abomasum. *Anim Feed Sci Technol* 2015;199:41–50.
8. Hughes JP. A simplified instrument for obtaining liver biopsies in cattle. *Am J Vet Res* 1962;23:1111–1113.
9. Akers RM, Denbow DM. *Anatomy and Physiology of Domestic Animals*. Ames, Iowa: Blackwell Publishing, 2008.
10. Wood PDP. Algebraic model of the lactation curve in cattle. *Nature* 1967;216:164–165.
11. Knight CH, Wilde CJ. Mammary cell changes during pregnancy and lactation. *Livest Prod Sci* 1993;35:3–19.
12. Wilde CJ, Addey CV, Li P, Fernig DG. Programmed cell death in bovine mammary tissue during lactation and involution. *Exp Physiol* 1997;82:943–953.
13. Capuco AV, Wood DL, Baldwin R, McLeod K, Paape MJ. Mammary cell number, proliferation, and apoptosis during a bovine lactation: Relation to milk production and effect of bST. *J Dairy Sci* 2001;84:2177–2187.
14. Pollott GE. Short communication: Do Holstein lactations of varied lengths have different characteristics? *J Dairy Sci* 2011; 94:6173–6180.